

## TECHNIQUES AND TECHNOLOGIES

# A Maxillary Implant Overdenture That Utilizes Angle-correcting Abutments

Lawrence J. Dario, DMD

Placement of dental implants to enhance complete denture stability and retention is a well-accepted treatment modality. Most implant overdenture abutments and related components require parallelism within approximately 10 degrees to function properly. Non-parallel implant placement as a result of flared maxillary bone may preclude the use of conventional implant overdenture abutments, requiring the use of costly custom abutments or bar prostheses. A case report is presented that illustrates the use of a new, 2-piece, angled overdenture abutment to accommodate non-parallel implant placement.

*J Prosthodont 2002;11:41-45. Copyright © 2002 by The American College of Prosthodontists.*

**INDEX WORDS:** complete denture, cementation, acrylic resin

**P**LACEMENT of dental implants to enhance complete denture stability and retention is a well-accepted treatment modality.<sup>1</sup> Most implant overdenture abutments and related components require parallelism within approximately 10 degrees to function properly.<sup>2</sup> Non-parallel implant placement as a result of flared maxillary bone may preclude the use of conventional implant overdenture abutments, requiring the use of costly custom abutments or bar prostheses.<sup>3</sup>

A 72-year-old Caucasian male presented with a chief complaint of poor retention with a complete maxillary denture. Clinical examination revealed a well-made denture with several years of service supported by a residual ridge of average dimension. Radiographic interpretation of panoramic and cephalometric views showed favorable bone height and width for implant placement from tooth position #4 to tooth position #14. After discussing various fixed and removable treatment alternatives, the patient selected a maxillary implant-supported overdenture with the option in the future of converting to a fixed prosthesis after placement of additional implants. The objective of this article is to present a simple, cost-effective technique to

achieve enhanced retention and stability on divergent implants utilizing a 2-piece, angled overdenture abutment.

### Surgical Treatment

Four 15 mm × 3.75 mm titanium and hydroxylapatite (HA)-coated Twist Max screw-shaped implants (Sulzer Dental, Carlsbad, CA) were placed by the prosthodontist under local anesthesia in tooth positions #4, 6, 11, and 13. Parallelism of the implants was not possible due to the flaring of the moderately resorbed maxilla. The implants were angled about 15 degrees buccally as seen in Fig 1. The full thickness flap was closed primarily with mattress and interrupted sutures, and the complete denture was relined with a chairside soft liner (Permasoft; Austenal, Chicago, IL). After a 5-month healing period, the implants were uncovered and healing abutments were placed (Figs 2 and 3). The complete denture was again relined with Permasoft.

### Prosthodontic Treatment and Technique

After soft tissue maturation, final impressions and maxillomandibular records were made in a conventional manner for the fabrication of a new maxillary denture. The healing abutments remained in place during the final impressions to register the positions of the implants for the final prosthesis. This facilitates relief of the denture during chairside overdenture abutment connection. A cobalt-chromium (Vitallium; Austenal) overdenture frame-

*Diplomate, American Board of Prosthodontics; Private Practice, Providence, RI.*

*Accepted November 5, 2001.*

*Correspondence to: Lawrence J. Dario, DMD, 200 Waterman Street, Providence, RI 02906-4039. E-mail: larydario@aol.com*

*Copyright © 2002 by The American College of Prosthodontists*

*1059-941X/02/1101-0008\$35.00/0*

*doi:10.1053/jpro.2002.31074*

work was then fabricated with an open palate for the patient's comfort. Wax try-in of the diagnostic set-up was then performed using the framework as a base. At this appointment, gingival cuff dimensions were recorded with a periodontal probe. The relative angles of the implants were estimated visually and approximated by provisionally placing fixed, cement-retained abutments of 0, 15, and 25 degrees to observe parallelism (Part numbers 1508, 1710, 1761; Sulzer Dental).

From the recorded measurements, 11–17-degree angle-correcting ERA abutments (Sterngold-ImplaMed, Attleboro, MA) of 2-mm cuff height were selected. Precise measurements of the angles required for parallelism are not necessary as the final ERA overdenture abutments are available in 0-, 5-, 11-, and 17-degree angles that allow for a range of implant divergence correction up to 34 degrees. These 2-piece abutments are unique in that they allow infinite adjustment of the corrected angle by the rotation of the inclined planes (Fig 4). The denture was then sent to the dental laboratory for final waxing and processing.

The processed denture was used for intraoral abutment connection following the method listed below. Laboratory processing of the angled abutments is generally not advised as these abutments are neither rotationally indexed to the implant nor thread timed. Therefore, they cannot be removed for processing and replaced on the implant fixture for delivery in precisely the same position.

1. Remove each healing abutment and screw the threaded apical base of the ERA 2-piece, angled abutment to the implant (Fig 5).
2. Securely place and snap the coronal attachment female of the ERA abutment into the apical base.
3. Rotate the coronal female parts of all the ERA abutments until best parallelism is achieved (Fig 6).
4. Intraorally record the radial position of the apical and coronal segments by placing a checkline axially through the 2 components of the angled abutment with a permanent ink marker pen (Fig 7).
5. Cement the 2 parts together with resin cement (C&B Cement; Bisco, Inc, Schaumburg, IL) in the position indicated by the marked checkline. This step may be done either intraorally or extraorally (Fig 8).

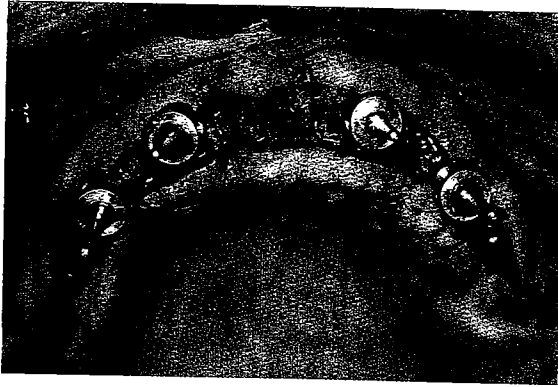
6. Place the retentive male element on the inserted, assembled abutment and relieve the denture so that the abutments will not prevent complete seating of the denture (Fig 9).
7. Place a small piece of rubber dam over the abutment apical to the retentive male element to block out undercuts (Fig 10).
8. Affix the retentive elements to the denture by placing a small amount of autopolymerizing resin (Pattern Resin; G C America, Inc, Alsip, IL) into the relieved areas of the denture, seating the prosthesis in the patient's mouth, and guiding the patient into maximum intercuspation. The patient applies and maintains light occlusal force while the resin polymerizes (Fig 11).
9. Remove excess autopolymerizing resin from the denture and insert the prosthesis (Fig 12). Note the autopolymerizing resin expressed on the intaglio surface of the denture, which is common with intraoral connection of attachments. Should this region be in a cosmetic area, the use of color-compatible, autopolymerizing resin is suggested. (The denture occlusion was established to articulate with a future, mandibular, metal ceramic prosthesis.)

## Discussion

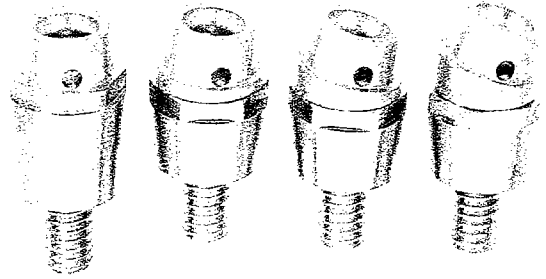
An overdenture supported by 2-4 fixtures is often presented as a "low cost" implant treatment alternative, as this therapy uses less implants and components than complete arch implant-supported fixed prosthesis. The "low cost" assumption is often based on using commercially available abutment components. When the use of custom abutments or bars is required to correct implant angulation, the cost of prosthesis fabrication may increase dramatically. In addition, there is often insufficient interocclusal space for bar placement, resulting in significant increases in denture thickness adversely affecting phonation and function.<sup>4-9</sup> This article describes a procedure using a low-cost, commercially available component to correct implant angulation problems.

## Summary

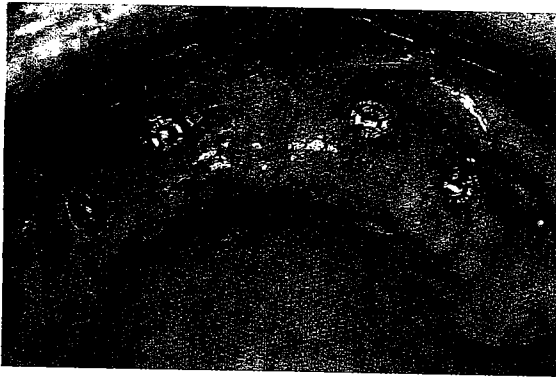A technique has been presented to fabricate overdentures on non-parallel implants utilizing commercially available, angle-correcting abutments. The technique minimizes laboratory expense and



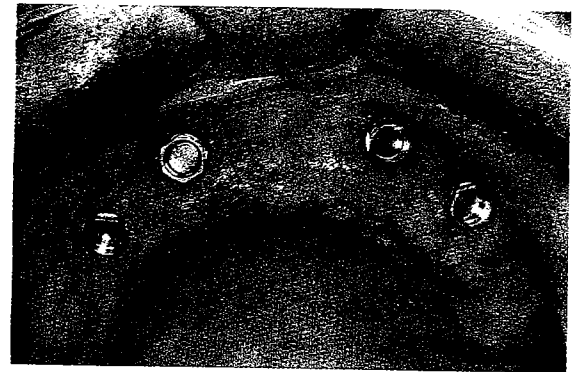
**Figure 1.** Spline (Sulzer Dental) implants were placed in the edentulous maxilla. Note the buccal flaring of about 15 degrees.



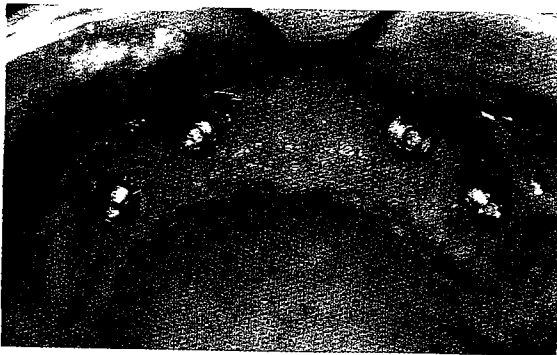**Figure 4.** Schematic of (left to right) 1-piece, 0 degree; 2-piece, 5 degree; 2-piece, 11 degree; and 2-piece, 17 degree variable angle-correcting ERA abutments. Note the inclined plane created in the 2-piece abutments by the horizontal axis of the apical component and the inclined axis of the coronal component. (Reprinted with permission from Sterngold-ImplaMed, Attleboro, MA.)



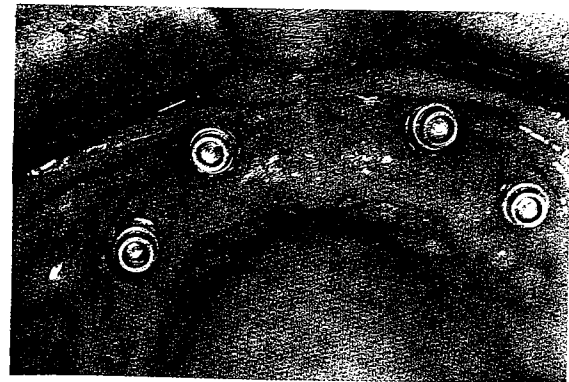
**Figure 2.** Implant positions after second stage healing are shown.




**Figure 5.** The apical section of the abutment has been placed.



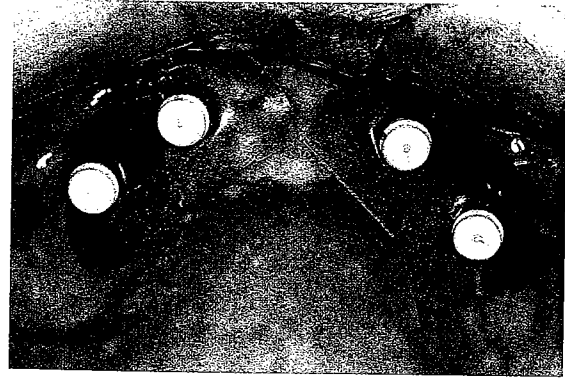
**Figure 3.** Healing abutments are placed before relining the denture.




**Figure 6.** The coronal section of the abutment has been rotated to achieve parallelism.



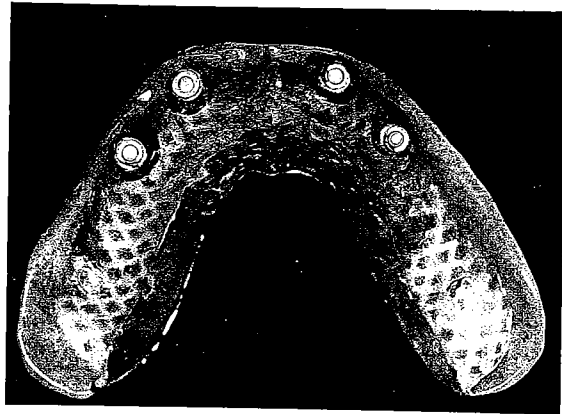
**Figure 7.** A checkline is made through both components with a permanent ink marker to record the radial position.



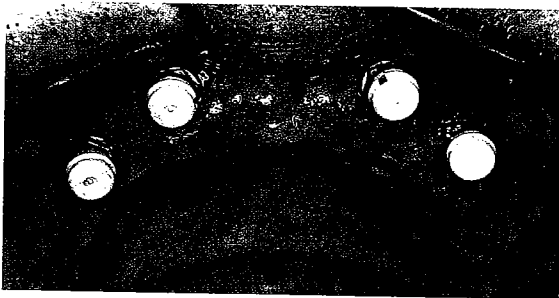
**Figure 10.** Placement of rubber dam blocks out undercuts before attaching the retentive elements to the denture.



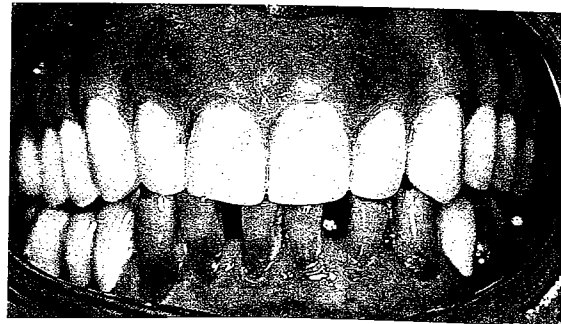
**Figure 8.** The abutments are cemented while maintaining parallelism.



**Figure 11.** The retentive elements are affixed to the denture intraorally with autopolymerizing resin.



**Figure 9.** The retentive elements are placed on the abutments.



**Figure 12.** The completed denture is shown.

chairtime and is a viable alternative to more costly and complicated bar-supported prostheses.

### References

1. Narhi TO, Hevinga M, Voorsmit R, et al: Maxillary overdentures retained by splinted and unsplinted implants: A retrospective study. *Int J Oral Maxillofac Implants* 2001;16:259-266
2. Staubli P: *Attachments & Implants Reference Manual*. San Mateo, CA, Attachments International, 1996
3. English C: Bar patterns in implant prosthodontics. *Implant Dent* 1994;3:217-229
4. Block MS, Kent JN, Finger IM: Use of the Integral implant for overdenture stabilization. *Int J Oral Maxillofac Implants* 1990;5:140-147
5. Ekfeldt A, Johansson L, Isaksson S: Implant-supported overdenture therapy: A retrospective study. *Int J Prosthodont* 1997;10:366-374
6. Finley JM: Restoring the edentulous maxilla using an implant-supported, matrix-assisted secondary casting. *J Prosthodont* 1998;7:35-39
7. Block M, Kent J: *Endosseous Implants for Maxillofacial Reconstruction*. Philadelphia, PA, Saunders, 1995, pp 158-192
8. Spiekerman H: *Color Atlas of Dental Medicine: Implantology*. New York, NY, Thieme, 1995, pp 210-237
9. Guerra L, Finger I, Block M: Tissue supported implant overdentures. *Implant Dent* 1992;1:69-77